

A Case Report on the Use of a Conjugated System of Myofascial Release for Shoulder Capsulitis

Ana Carolina Negraes Canelada^{1,2}, Fernanda Mansano Carbinatto^{1,3}, Antonio Eduardo de Aquino Junior^{1,3*} and Vanderlei Salvador Bagnato^{1,2,4}

¹Instituto de Física de São Carlos, Universidade de São Paulo, São Carlos, São Paulo, Brasil

²Programa de Pós-Graduação em Biotecnologia, Universidade Federal de São Carlos, São Carlos, São Paulo, Brasil

³Clinica MultFISIO Brasil, São Carlos, São Paulo, Brasil

⁴Hagler Institute for Advanced Study, Texas A&M University, Texas, United States of America

Abstract

The adhesive capsulitis causes stiffness and pain, limiting both active and passive shoulder movement. The prevalence is estimated between 2% to 5% of the general population, with women aged 40 to 60 years being the population most affected by the disease. The types of treatment show evaluation between 2 or 3 years, but is not yet fully established. Among the non-invasive and non-pharmacological forms of treatment that are currently used is physiotherapy. This study aimed to evaluate the combined therapy of myofascial release and photobiostimulation, associating the action of mechanical traction with the fibres of the muscle fascia as well as the photobiomodulatory action of the therapeutic laser was used, as a form of assessment, the disabilities of the arm, shoulder and hand questionnaire (DASH) and the visual analogue scale. It was observed the control of the local inflammatory process and the release of adhesion of the glenohumeral joint capsule, in a period of 6 weeks (12 sessions). This results show a new and promising possibility of treatment for adhesive capsulitis, allowing the return of quality of life for patients in less time.

Keywords: Adhesive capsulitis; Myofascial release; Fotobiomodulation

Introduction

A common shoulder joint disease with the ability to decrease joint range, is adhesive capsulitis, which causes stiffness and pain, limiting both active and passive shoulder movement [1,2]. It is observed as an estimated prevalence of 2% to 5% of the general population, with women aged 40 to 60 years being the population most affected by the disease [2]. Its pathology reports to a chronic inflammatory condition of the subsynovial layer of the capsule, producing capsular thickening, fibrosis and adhesion of the capsule, both to itself and to the anatomical neck of the humerus [1].

Treatment for adhesive capsulitis is not yet fully established [2]. Among the non-invasive and non-pharmacological forms of treatment that are currently used are physiotherapy and acupuncture [2,3,4]. Within physiotherapy, we can highlight therapeutic ultrasound [5], photobiomodulation [6], transcutaneous electrical nerve stimulation [7], exercises [8] and myofascial release [9].

This study aimed to evaluate the combined therapy of myofascial release and photobiostimulation, using equipment developed by the São Carlos Institute of Physics. Thus, the action of mechanical traction was associated with the muscle fascia fibers with the photobiomodulating action of the therapeutic laser, enabling the promotion of myofascial release, fiber realignment [10], analgesia, anti-inflammatory action [11], allowing the tissue injured person has a more accelerated recovery through the increased production of ATP [11].

Materials and Method

Study and patient

The project was approved by the Ethics Committee for Human Beings of the Santa Casa de Misericórdia of São Carlos, under the number CAAE 40296320.5.0000.8148, in accordance with resolution 466/2012 and resolution 510/2016. The patient, a 57-year-old Caucasian male, presented a medical report reporting adhesive capsulitis in both shoulders, with an existing lesion for 2 years. The patient had joint limitation and severe pain, limiting his professional functions in the area of structural repair and maintenance, as well as preventing

him from performing leisure activities such as cycling. The origin of capsulitis is intrinsic, by repetitive strain, without previous occurrences of other diseases. During the study period, the patient did not use any medication.

Equipment and protocol

The prototype equipment, called "Roller Laser", developed by the Technical Support Laboratory of the São Carlos Institute of Physics, University of São Paulo, allows, through waits, muscle rotation and traction, associating low laser emission intensity, at 660 nm and 808 nm wavelengths, with a power of 100 mW, totaling 30 minutes of application, totaling 90 J of energy. Its rotation and traction characteristic allows the release of the muscle fascia, and the photobiomodulation action allows anti-inflammatory and analgesic actions, in addition to the production of ATP.

The protocol was carried out during 12 sessions, twice a week, lasting 30 minutes, using the spheres for myofascial release in a movement parallel to the nerve fibers. The action of photobiostimulation was performed using the laser at a wavelength of 808 nm, 100 mW of power, during the entire application period (30 minutes), and totaling 90 J.

Area of application

The application region comprises the muscles responsible for the movements of shoulder flexion and extension, abduction and adduction, internal and external rotation, including the pectoralis major muscle (clavicular portion), the anterior deltoid muscle (in

***Corresponding author:** Antonio Eduardo de Aquino Junior, Instituto de Física de São Carlos, Universidade de São Paulo, São Carlos, São Paulo, Brasil, Tel: +6016-6539368; E-mail: antonioaquino@ifsc.usp.br

Received July 28, 2021; **Accepted** August 21, 2021; **Published** August 28, 2021

Citation: Canelada ACN, Carbinatto FM, Junior AEA, Bagnato VS (2021) A Case Report on the Use of a Conjugated System of Myofascial Release for Shoulder Capsulitis. J Nov Physiother 11: 476.

Copyright: © 2021 Canelada ACN, et al. This is an open-access article distributed under the terms of the Creative Commons Attribution License, which permits unrestricted use, distribution, and reproduction in any medium, provided the original author and source are credited.

the middle fiber portion), the posterior deltoid muscle and lateral deltoid muscle, the biceps muscle, the latissimus dorsi muscle and the muscles that make up the rotator cuff, which are the supraspinatus, infraspinatus, subscapularis and teres minor muscles.

Questionnaire

As a form of assessment, the Disabilities of the arm, shoulder and hand questionnaire (DASH), specifically for the assessment of upper limb movements and the Visual Analogue Scale were performed in two moments, before treatment and after session 12 of treatment, able to assess the patient's pain.

Results

The use of technology combined with mechanical traction and photobiomodulation shows its results in monitoring a patient affected by adhesive capsulitis. The image composition in Figure 1 (A/B/C/D) shows the patient's evolution over 12 sessions. It is possible to observe the evolution in the degree of flexion of both shoulders (right and left), increasing from 120° to 180° in just 12 sessions.

Still, in observation of the composition of images in Figure 2, it is possible to observe an improvement in posture due to a significant visual change in the rotation of the right and left shoulders. Such movement limitation made it impossible to maintain posture. The limitations of the upper limbs provided the patient with the need to

stop recreational activities such as cycling, as well as great limitation of professional activities.

The use of the Disabilities of the arm, shoulder and hand (DASH) questionnaire to assess before and after treatment allowed the analysis of processes such as difficulty in performing activities; intensity of symptoms of pain, weakness stiffness and paresthesia; commitment of social activities; difficulty to sleep; and psychological commitment. It is possible in Figure 3 to observe percentage variations of improvement in almost all the variables mentioned, with a total improvement of 38.5%. In this figure, we can highlight the improvement reported in relation to difficulty in performing activities (43.6%) and intensity of symptoms of pain, weakness stiffness and paresthesia (50%).

Figure 4 shows the variation between before and after treatment, in the amount of notes observed in the DASH questionnaire, in relation to conditions of limitation. The wide change in score distribution, varying conditions of limitation in the situation before and after indicate no limitation from 13.33% to 83.33%, mild limitation from 83.33% to 16.66% and moderate limitation from 3.33% to 0%. Conditions of severely limited and very severely limited were not pointed out.

Figure 5 illustrates the temporal evolution of pain when the Visual Analogue Scale is evaluated. It is observed that in 12 sessions, the evolution continues and with brief plateaus, reducing from 6 to 2, obtaining 66.5% improvement in pain.

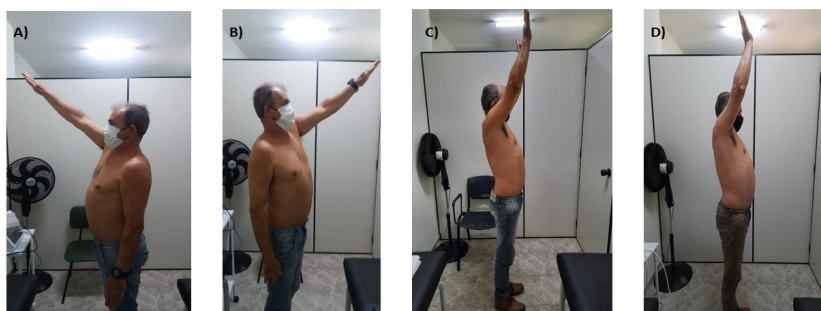

Figure 1: A) Patient before first session in initial evaluation realizing the shoulder flexion (120°). The angle of movement is much harmed; B) Patient after 10 sessions (170°). The angle of movement shows greater breadth; C) Patient after 12 sessions (180°). The angle of movement is restored.

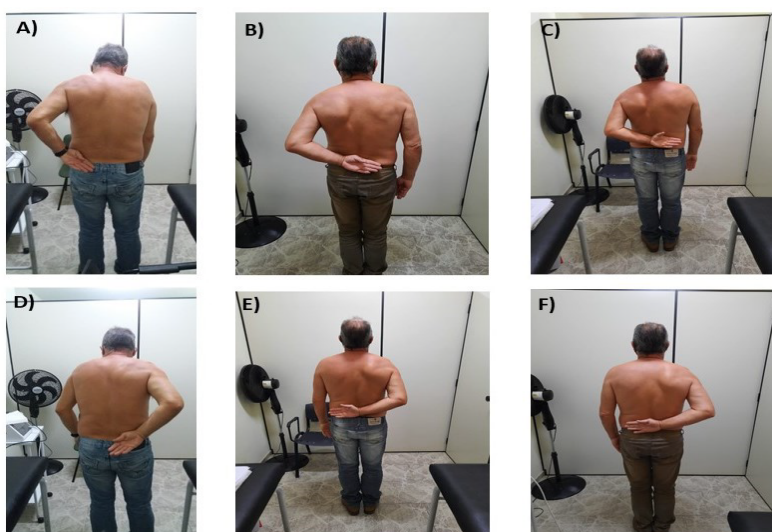


Figure 2: A/D) Patient before first session in initial evaluation. It is possible to observe that inadequate internal rotation of shoulder, causing negative and irregular posture; B/E) Patient after 10 sessions. There is a better internal rotation of shoulder, promoting the better of posture; C/F) patient after 12 sessions. Normalizing of posture.

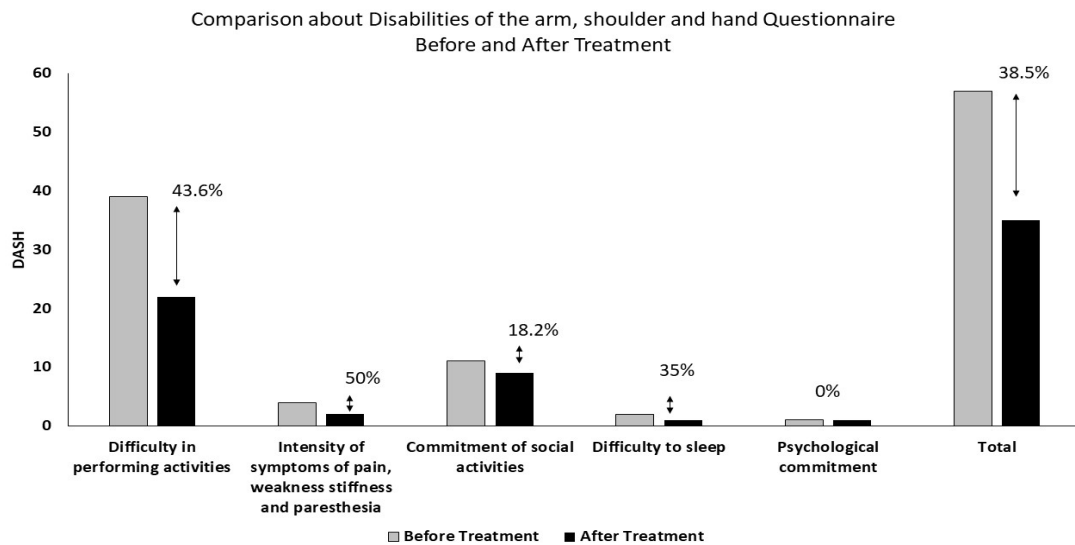


Figure 3: DASH - Disabilities of the arm, shoulder and hand, represented on average. Data are presented with percentage difference, showing values from before and after treatment.

	Initial		Final	
	Frequency	%	Frequency	%
No limitation	4	13.33	25	83.33
Light limitation	25	83.33	5	16.66
Moderate limitation	1	3.33	0	0
Severe limitation	0	0	0	0
Very severe limitation	0	0	0	0
Total	30	99.99	30	99.99

Figure 4: DASH - Disabilities of the arm, shoulder and hand, relating the percentage of pointing in relation to the limitation of movement. The data of no limitation, light limitation, moderate limitation, severe limitation and very severe limitation, at a time before and after the treatment, are indicated.

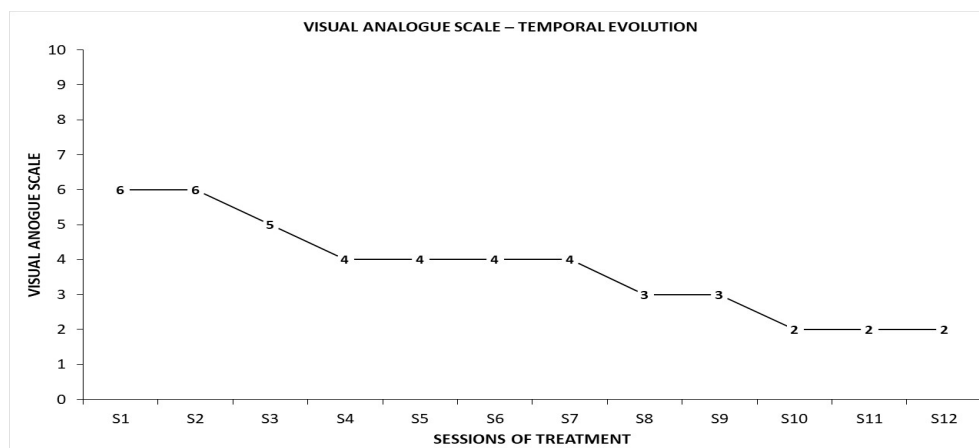


Figure 5: Visual Analogue Scale, represented on average. Data are presented in temporal evolution of the treatment.

Discussion

The lack of efficacy and definition in the means of treatment for adhesive capsulitis brings the need for new proposals for non-invasive and non-pharmacological therapeutic actions. Traditional physiotherapy therapies result in a treatment time of 2 to 3 years in duration [12]. Thus, adhesive capsulitis, as a disease, results in a painful condition and an inflammatory process that causes joint limitation [1,2].

In this context, the possibility of a combined system that allows myofascial release and photobiomodulatory action brings with it the condition of muscle fascia reorganization and muscle pain relief, as well as analgesics, anti-inflammatory action and increased production of ATP, for a tissue seeking kinesic homeostasis.

Thus, our study evaluated the combined action of myofascial release and photobiostimulation in a patient with adhesive capsulitis, where, in addition to pain, it affected both shoulders, limiting joint movement to a maximum of 120°. An established process of 12 sessions, 2 sessions per week, allowed the patient to reduce pain, as seen in Figure 5 and, at the same time, to increase joint range of motion, returning to 180°. This condition, where the traction of the muscle fascia in action parallel to the fibers, performed by the spheres present in the equipment, results in the reorganization of the muscle fascia, helping to release the adhesions of the glenohumeral joint capsule [3], without stress manual touch mechanic. Still, the photobiomodulating action allows direct action on pain, through analgesia, as well as the anti-inflammatory benefit [11] for tendons and bursae.

The control of the local inflammatory process and the release of adhesion of the glenohumeral joint capsule, without the use of invasive or medicinal resources, in a period of 6 weeks (12 sessions), foresees a new and promising possibility of treatment for adhesive capsulitis, allowing the return of quality of life for patients in less time.

Conclusion

Adhesive capsulitis, as an inflammatory and painful condition, is a disease that needs more studies and new technologies that allow a more effective and shorter treatment. Our study, still a case study, showed promise to the point of being able to reduce the patient's treatment period

to 6 weeks, restoring their quality of life. Our work, in full development, could be a new watershed in the treatment of adhesive capsulitis.

Ethical Approval

This study was approved by the Research Ethics Committee and the National Research Ethics Committee through CAAE 40296320.5.0000.8148.

Conflicts of Interest

All authors confirm that there is no conflict of interest.

References

1. Neviaser AS, Neviaser RJ (2011) Adhesive Capsulitis of the Shoulder. J Am Acad Orthop Surg 19: 536-542.
2. Ramirez J (2019) Adhesive Capsulitis: Diagnosis and Management. Am Fam Physician 99: 297-300.
3. Redler L, Dennis E (2019) Treatment of Adhesive Capsulitis of Shoulder. J Am Acad Orthop Surg 27: e544-e554.
4. Chen X, Fan H, Chen J, Fan H, Wu P (2020) Bee venom acupuncture for adhesive capsulitis: A protocol for systematic review and meta-analysis. Medicine 99: e19975.
5. Balci TO, Turk AC, Sahin F, Kotevoglun N, Kuran B (2018) Efficacy of therapeutic ultrasound in treatment of adhesive capsulitis: A prospective double blind placebo-controlled randomized trial. J Back Musculoskelet Rehabil 31: 955-961.
6. Ip D, Fu N (2015) Two-year follow-up of low-level laser therapy for elderly with painful adhesive capsulitis of the shoulder. J Pain Res 8: 247-252.
7. Rawat P, Eapen C, Seema KP (2017) Effect of rotator cuff strengthening as an adjunct to standard care in subjects with adhesive capsulitis: A randomized controlled trial. J Hand Ther 30: 235-241.
8. Kelly MJ, Shaffer MA, Kuhn JE, Michener LA, Seitz AL, et al. (2013) Shoulder pain and mobility deficits: Adhesive capsulitis. J Orthop Sports Phys Ther 43: A1-A31.
9. Beutler A (2018) Musculoskeletal Therapies: Adjunctive Physical Therapy. FP Essent 470: 16-20.
10. Beardsley C, Skarabot J (2015) Effects of Self-myofascial release: A systematic review. J Bodyw Mov Ther 19: 747-758.
11. Karu T (1999) Primary and secondary mechanisms of action of visible to near-IR radiation on cells. J Photochem Photobiol B 49: 1-17.
12. Page MJ, Green S, Kramer S, Johnston RV, McBain B, et al. (2014) Manual therapy and exercise for adhesive capsulitis (frozen shoulder). Cochrane Database Syst Rev Pp: 1-177.